

Practical Recommendations and Perspectives on Cardiac Screening for Healthy Pediatric Athletes

Sarina K. Behera, MD¹; Tanaya Pattnaik²; and Anthony Luke, MD, MPH, FACSM^{2,3}

Abstract:

Primary care providers often are asked to perform the preparticipation physical exam and cardiac screening of pediatric athletes. It can be challenging to evaluate which athletes may require further cardiac evaluation and specialist referral based on a focused history and physical. There is considerable controversy surrounding mass electrocardiogram (ECG) screening of athletes in the United States. The ECG is one of several diagnostic tests used by pediatric cardiologists in the evaluation of underlying heart disease in young athletes. This article reviews cardiac conditions associated with sudden death, discusses pertinent findings on history and physical, and provides clinically relevant information for practitioners who are deciding which patients to refer for detailed cardiac evaluation.

refers to asymptomatic patients 18 yr and younger who have no known cardiac conditions at the time of sports preparticipation screening.

CAUSES OF SUDDEN CARDIAC DEATH

Sudden death of a young athlete on the field or court is a rare but tragic event, occurring in about two in 100,000 high-school athletes each year (11,27). Hypertrophic cardiomyopathy (HCM) is the most common cause of sudden death in young athletes (Figure) and accounts for 36% of cases (33). In

INTRODUCTION

There is considerable controversy surrounding the utility and cost effectiveness of screening electrocardiograms (ECG) and echocardiograms on young athletes in the United States. Most primary care practitioners are not involved in community-based screening but frequently perform sports physicals on individual children and teenagers in the office. In general, pediatric cardiologists who are well trained to perform cardiac screening are not the practitioners providing first-line care to these young, healthy athletes. The objectives of this article are to provide primary care practitioners with a review of cardiac conditions associated with sudden death in the active pediatric population, to discuss aspects of the history and physical that may prompt further testing or specialist referral, and to highlight some of the findings on ECG and echocardiograms that may be consistent with cardiac conditions and/or athlete's heart. For the purposes of this review, "healthy pediatric athletes"

HCM, a genetic mutation causes asymmetric hypertrophy of the ventricular septum, which can lead to left ventricular outflow tract obstruction and fatal ventricular arrhythmias. African-American male athletes are at the highest risk for sudden death from HCM (29). The second most common cause of sudden cardiac death in athletes includes anomalous origin of a main coronary artery, usually arising from the wrong aortic sinus and coursing between the pulmonary artery and aorta (33). Coronary artery anomalies can be suggested by episodes of chest pain and/or syncope with exercise but often go undiagnosed and are identified at autopsy (4). The mechanism of sudden death likely is myocardial ischemia (4,49).

Other less common causes of sudden death that are related to anatomic lesions include aortic root rupture, aortic stenosis, and arrhythmogenic right ventricular dysplasia (ARVD) (33). Connective tissue disorders, including Marfan syndrome, can lead to weakening of the aortic wall, development of aortic root dilatation, and increased risk of aortic rupture. Marfan syndrome can be suggested by physical exam and occurs equally in males and females across race and ethnic groups (47). Congenital aortic stenosis refers to thickening and narrowing of the aortic valve, which is often detected by a significant systolic murmur in childhood. Children diagnosed with congenital aortic stenosis should be followed routinely by a pediatric cardiologist who evaluates the degree of stenosis, determines timing of intervention, and restricts sports participation according to guidelines developed for children with known congenital heart disease (15). ARVD is a hereditary disorder caused by fibrosis

¹Pediatric Cardiology, Sutter Pacific Medical Foundation, California Pacific Medical Center, San Francisco, CA; ²Orthopaedic Surgery, University of California, San Francisco, CA; ³Family & Community Medicine, University of California, San Francisco, CA

Address for correspondence: Sarina K. Behera, MD, Sutter Pacific Medical Foundation, California Pacific Medical Center, 3700 California Street, First Floor, Ste 1560, San Francisco, CA 94118 (E-mail: beheras@sutterhealth.org).

1537-890X/1002/90-98

Current Sports Medicine Reports

Copyright © 2011 by the American College of Sports Medicine

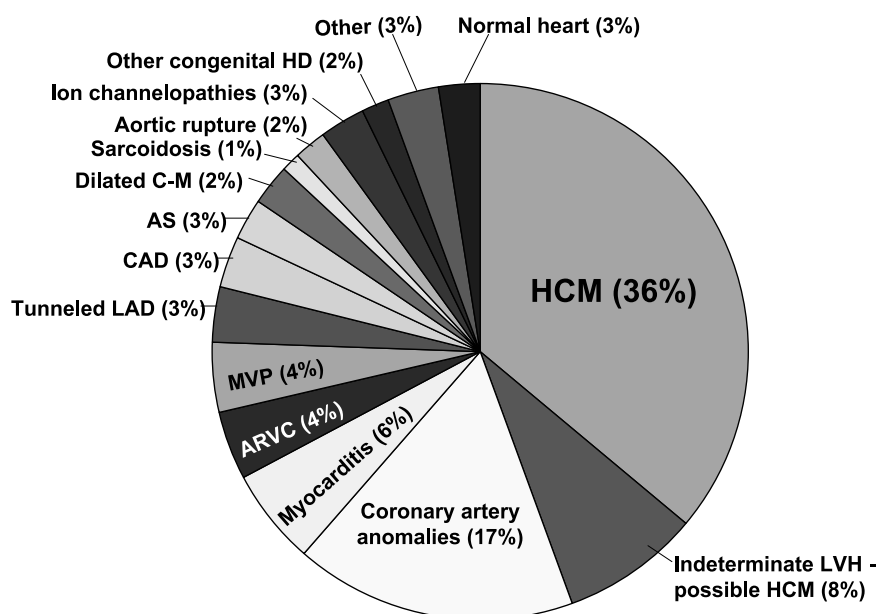


Figure: Distribution of cardiovascular causes of sudden death in 1435 young competitive athletes. From the Minneapolis Heart Institute Foundation Registry, 1980 to 2005. ARVC indicates arrhythmogenic right ventricular cardiomyopathy; AS, aortic stenosis; CAD, coronary artery disease; C-M, cardiomyopathy; HD, heart disease; LAD, left anterior descending; LVH, left ventricular hypertrophy; and MVP, mitral valve prolapse. (Borrowed from Maron BJ, Thompson PD, Ackerman MJ, et al. Recommendations and considerations related to pre-participation screening for cardiovascular abnormalities in competitive athletes: 2007 update: a scientific statement from the American Heart Association Council on Nutrition, Physical Activity, and Metabolism: endorsed by the American College of Cardiology Foundation. *Circulation*. 2007; 115:1643–55. Used with permission).

and fatty tissue infiltration of the right ventricle. It is rare and difficult to detect in young athletes in the United States but is the most common cause of sudden death in athletes in Italy (31). The first presentation of ARVD can be sudden death due to sustained ventricular arrhythmias (24).

Arrhythmia syndromes comprise another group of diagnoses that can lead to sudden death in athletes. In Wolff-Parkinson-White (WPW) syndrome, an accessory pathway leads to preexcitation (early depolarization) of the ventricles and episodes of paroxysmal supraventricular tachycardia. Many athletes are asymptomatic but may demonstrate pre-excitation (slurred upstroke in the QRS complex, prolonged QRS interval) on a screening ECG. Sudden death in WPW has a low incidence (0.2%) (13) but can occur when there is accelerated conduction through the accessory pathway leading to atrial fibrillation with a rapid ventricular response (19). Athletes with WPW may be at increased risk of developing ventricular fibrillation (17). Other diagnoses that may be identified by a screening ECG include cardiac channelopathies, such as long QT and Brugada syndromes, which can lead to episodes of ventricular tachycardia and ventricular fibrillation. These are rare hereditary disorders that involve abnormalities in cardiac ion channels. Patients with ion channelopathies may have significant family histories of early sudden death.

ATHLETE'S HEART

A variety of morphological changes can occur in the hearts of highly trained young athletes. Athlete's heart refers to changes in the heart that are due to endurance and/or strength training, including left ventricular dilatation, mild concentric left ventricular hypertrophy, and left atrial en-

largement (9,26). Aerobic exercise (*e.g.*, running and cycling) leads to both increased left ventricular wall thickness and cavity size, whereas anaerobic exercise (*e.g.*, weightlifting) leads to increased left ventricular wall thickness without a significant change in cavity size (41,44).

It can be challenging to differentiate athlete's heart from pathologic changes due to HCM. In athlete's heart, the hypertrophy in response to training tends to be symmetric and concentric; all of the ventricle walls appear mildly thickened. In HCM, the hypertrophy generally is asymmetric, with most cases showing disproportionate hypertrophy of the ventricular septum with relatively normal thickness of the other ventricle walls. Age, body surface area, gender, and race affect normative values for wall thickness in athletes.

There are limited pediatric data regarding athlete's heart. Children typically are evaluated using wall thickness norms based on body surface area rather than chronological age. One study in elite adolescent athletes aged 14 to 18 yr recommended that HCM should be considered when wall thickness is greater than 11 mm in Caucasian females and 12 mm in Caucasian males (45). Female athletes are less prone to develop athlete's heart than male athletes because of smaller left ventricular cavity size, wall thickness, and lower cardiac output during exercise (41). Interestingly, females are much less likely to experience sudden death during exertion compared with males (31). In contrast, African-American male athletes are at the highest risk for sudden death and typically have higher wall thickness at baseline compared with Caucasian athletes (3,20,29). In summary, teenage athletes with septal wall thickness greater than 11 mm in females and 12 mm in males may be

concerning for underlying cardiomyopathy, and referral to pediatric cardiology should be considered. In children, septal wall thickness greater than two standard deviations above the mean (based on body surface area) is suspicious for HCM, although norms for specific ethnic populations need to be established.

CARDIAC CONSIDERATIONS DURING THE PREPARTICIPATION EXAM

When screening athletes for underlying cardiac conditions, it is very important to implement a focused history and physical exam. The American Heart Association (AHA)

TABLE 1
The 12-element AHA recommendations for preparticipation cardiovascular screening of competitive athletes.

Medical history*
Personal history
1. Exertional chest pain/discomfort
2. Unexplained syncope/near-syncope†
3. Excessive exertional and unexplained dyspnea/fatigue, associated with exercise
4. Prior recognition of a heart murmur
5. Elevated systemic blood pressure
Family history
6. Premature death (sudden and unexpected, or otherwise) before age 50 years due to heart disease, in 1 or more relatives
7. Disability from heart disease in a close relative <50 years old
8. Specific knowledge of certain cardiac conditions in family members: hypertrophic or dilated cardiomyopathy, long-QT syndrome or other ion channelopathies, Marfan syndrome, or clinically important arrhythmias
Physical examination
9. Heart murmur‡
10. Femoral pulses to exclude aortic coarctation
11. Physical stigmata of Marfan syndrome
12. Brachial artery blood pressure (sitting position)§

*Parental verification is recommended for high school and middle school athletes.

†Judged not to be neurocardiogenic (vasovagal); of particular concern when related to exertion.

‡Auscultation should be performed in both supine and standing positions (or with Valsalva maneuver), particularly to identify murmurs of dynamic left ventricular outflow tract obstruction.

§Preferably, taken in both arms.³⁷

(Adapted from Maron BJ, Thompson PD, Ackerman MJ, et al. Recommendations and considerations related to preparticipation screening for cardiovascular abnormalities in competitive athletes: 2007 update: a scientific statement from the American Heart Association Council on Nutrition, Physical Activity, and Metabolism: endorsed by the American College of Cardiology Foundation. *Circulation*. 2007; 115:1643–455. Used with permission).

proposed a set of screening questions (Table 1) to help primary care providers identify possible cardiovascular concerns that may warrant further evaluation and specialist referral (33).

The personal history should focus on cardiovascular symptoms the patient experiences *with exercise*, particularly chest pain, excessive dyspnea, and/or near-syncope/syncope (33). The physical exam may be normal in a young athlete with an underlying heart condition, which can make the personal and family history even more significant. A significant family history for early sudden death and/or certain cardiac conditions (e.g., Marfan syndrome, long QT syndrome, HCM) can help raise concern for these diseases in an asymptomatic patient (46).

Pediatric cardiologists perform focused history and physical exams that incorporate the AHA guidelines but also draw from their own training and clinical experiences. For instance, although *chest pain* is a common complaint referred to a general pediatric cardiologist, it very rarely is due to cardiac causes in the pediatric population (10,12,18). Common benign causes of chest pain in older children and teenagers include costochondritis, precordial catch syndrome (pleural pain with breathing), stress, and anxiety. A detailed history of the symptoms can be very helpful in identifying noncardiac causes. Pediatric patients with non-cardiac chest pain often report that the pain is self-limited, independent of exercise, and not associated with other symptoms. Chest pain that is triggered by intense exercise and associated with other concerning symptoms, such as radiating pain, lightheadedness, syncope, and/or tachycardia, is significantly more suggestive of a cardiac etiology. Underlying problems that can cause cardiac ischemia in young athletes can include anomalous origin of a coronary artery, Kawasaki disease with coronary abnormalities, and familial hypercholesterolemia (18).

Shortness of breath on exertion more commonly is due to asthma and/or deconditioning than to cardiac chest pain, particularly in obese children (10). Shortness of breath with exercise can be a difficult symptom to explore in detail with children. Questions related to the degree of dyspnea (beyond what would be expected with exercise), associated symptoms, and the timing of dyspnea (e.g., at the onset of exercise vs after intense exercise) may be helpful. Cardiopulmonary exercise testing, weight loss, and/or trial of albuterol prior to exercise also can be important in the evaluation of isolated exertional dyspnea.

Palpitations are not included in the AHA 12-element history and physical but comprise another common chief complaint in older children and teenagers presenting to pediatric cardiologists (34). Athletes who complain of palpitations with exercise may raise concern for arrhythmias (e.g., catecholaminergic polymorphic ventricular tachycardia, or long QT syndrome). Again, the history can be very helpful in obtaining an accurate description of the palpitations. When asking about palpitations, it is important to ascertain the heart rate reported during the episode. Often children will describe a “hard” and “pounding” heartbeat as opposed to a rapid heart rate. It can be helpful to ask the patient to tap out the rate or compare it to target heart rates reached during exercise. In practice, one can teach the patient and parents how to take a radial pulse for

15 s and multiply by four. The family is asked to keep a diary of palpitation episodes. They are instructed to write down the times the episode starts and stops, patient's activity at the time (playing, exercising, resting), and the heart rate. Arrhythmogenic causes of sudden death tend to generate heart rates above what would be expected with intense exercise. A detailed description of the onset and resolution of the episode is valuable. Arrhythmias tend to start and stop suddenly instead of gradually increasing and decreasing in heart rate.



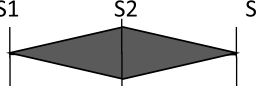

Syncope is common in older children and teenagers, but it usually is vasovagal and rarely cardiac in etiology (6). Common triggers for noncardiac syncope include dehydration, heat, anxiety, fear, and rising from a supine position (6). Syncope with the following characteristics suggests an underlying heart condition: exercise-induced, associated symptoms (chest pain, dyspnea, and/or palpitations), and/or significant family history (e.g., HCM, long QT syndrome, early sudden death) (50). Therefore, in a young athlete, syncope during strenuous exercise is suspicious for heart disease associated with sudden death and warrants a detailed cardiac evaluation (46).

Other elements of the medical history can impact the need for further cardiac screening in athletes. Many athletes will have other common diagnoses, such as obesity and asthma, which may cause similar symptoms and decrease the suspicion

for cardiac disease (10). *Use of medical and nonprescription substances*, including dietary supplements, energy drinks, steroids, recreational drugs, and/or stimulant medications, may be relevant. Approximately 10% of children have attention deficit hyperactivity disorder (ADHD), many of whom are on stimulant medication. Although there are limited data on the risk of sudden death in athletes on ADHD medications, health care providers may have a lower threshold to pursue cardiac screening in these patients. Parents should be requested to leave the exam room temporarily to ask the patient about use of anabolic steroids, alcohol, and recreational drugs. Anabolic steroids can lead to cardiac hypertrophy and have been associated with sudden cardiac death (48). Cocaine use has been implicated in myocardial ischemia, infarction, arrhythmias, cardiomyopathy, and sudden death (23).

Questions about a history of *early sudden death in the family* should be asked to both the athlete and the parents, who may be more familiar with the family history. It can be helpful to explore unexpected deaths with questions such as "Has anyone in the family drowned who knew how to swim? Has anyone been in a fatal car accident without being under the influence of alcohol? Have any infants in the family died from unknown causes or a heart condition?" Questions about abnormal heart rhythms and pacemakers also may uncover familial arrhythmia syndromes. Family history of

TABLE 2.
Typical characteristics of normal and pathologic murmurs.

Murmur Characteristic	Typical of Normal Murmurs	Typical of Pathologic Murmurs
Grade	I/VI to II/VI	≥III/VI
Pitch	Low	Medium to high
Quality	Soft, vibratory, musical	Harsh, blowing, crescendo-decrescendo
Timing	Short mid-systolic murmur 	Long systolic murmur  Continuous (systole and diastole)  Diastolic murmur 
Radiation	Does not radiate significantly	Back (pulmonary stenosis, coarctation), apex (mitral regurgitation), neck (aortic stenosis)
Changes with position	Louder when supine	Louder when standing
Precordium	Quiet, normal apical impulse	Dynamic with thrill or heave, strong and/or displaced apical impulse
Other positive findings on history and physical	None	Present

sudden death and syncope more often is found in patients with long QT syndrome than in patients with other causes of syncope (6).

A careful clinical exam is needed to pick up abnormalities, as the majority of physical examinations will be normal. Many of the hereditary syndromes involved in sudden cardiac death have no apparent physical exam signs, except for Marfan syndrome (tall, thin stature, pectus deformity, joint hypermobility, scoliosis, and arm span greater than height) (47). A heart murmur and/or elevated blood pressure on physical exam may warrant further evaluation. A heart murmur in an adolescent can be a normal finding, but it also can be suggestive of HCM and other cardiac diagnoses (Table 2). Maneuvers such as bearing down and rising from a supine to standing position will increase the pitch of the murmur when there is left ventricular outflow tract obstruction in HCM (46). In contrast, patients with HCM who do not have left ventricular outflow tract obstruction might not have a murmur. An S3 heart sound can be normal in healthy teenagers, although it is considered abnormal in adults. In contrast, an S4 heart sound (heard with decreased ventricular compliance) is abnormal in all age groups. Other physical exam findings that may suggest cardiac diagnoses include jugular venous distension, hepatomegaly, hyperactive precordium/thrill, and displaced apical impulse. Hypertension should be evaluated on multiple occasions and may require 24-h ambulatory monitoring to diagnose essential hypertension (35,43), which is becoming more common with the childhood obesity epidemic. Secondary causes of hypertension in pediatric patients include aortic coarctation, renal artery stenosis, chronic renal disease, and pheochromocytoma. Coarctation of the aorta can be suggested by a non-specific murmur, decreased femoral pulses, and hypertension and confirmed by echocardiogram.

PEDIATRIC CARDIOLOGY PERSPECTIVE

A variety of tests make up the cardiologist's armamentarium in the evaluation of athletes with concerns raised by a focused history and physical (Tables 3 and 4). The test most often obtained by referring providers and cardiologists is the resting 12-lead ECG, which has high sensitivity (60%–91%) for cardiac conditions associated with sudden death, but low specificity, particularly in athletic populations because of several mild ECG abnormalities associated with athlete's heart (2,8,33). Most cardiologists would not argue the benefits of obtaining an ECG for an athlete with concerning history, signs, and/or symptoms identified by the focused AHA history and physical. In a referral patient population, the ECG is a quick, easy, and inexpensive test compared with other cardiology procedures. Evaluation of an individual patient referred to a pediatric cardiology office is a very different scenario from the significant resources required for community-wide screening of all young athletes.

Recent guidelines have been published by European cardiology societies that propose that certain ECG abnormalities found in athletes, including sinus bradycardia, first-degree atrioventricular block, early repolarization, incomplete right bundle branch block, and isolated QRS voltage criteria for left ventricular hypertrophy, are benign and may not require further evaluation (8). There are various ECG criteria for

TABLE 3.

ECG findings in the cardiac evaluation of athletes.

Possible Diagnosis	ECG Findings
Athletic training-related changes ¹	Sinus bradycardia
	First degree AV block
	Early repolarization
	Incomplete right bundle branch block
	Isolated left ventricular hypertrophy
HCM	Left ventricular hypertrophy
	Left axis deviation
	Left atrial enlargement
	ST and T wave abnormalities
	Pathologic Q waves
ARVD	Postexcitation low-amplitude potentials (epsilon waves)
	T wave inversion in adults (normal in children and teenagers)
	Wide QRS and prolonged S-wave upstroke in V1-V3
Long QT syndrome	Long QT interval
	T wave abnormalities
Short QT syndrome	Short QT interval
	Absent ST segment
	High amplitude T waves
Wolff-Parkinson-White syndrome	Short PR interval
	Slurred upstroke of QRS (delta wave)
	Prolonged QRS
Brugada syndrome	J-point elevation
	Downsloping of ST segment

ARVD = arrhythmogenic right ventricular dysplasia; ECG = electrocardiogram; HCM = hypertrophic cardiomyopathy.

diagnosing left ventricular hypertrophy, many of which have low sensitivity for HCM (16). Non-QRS voltage findings of left ventricular hypertrophy that may suggest HCM include left-axis deviation, left atrial enlargement, and ST and T-wave abnormalities. Inverted T-waves in a postpubertal athlete can suggest any of the following: ARVD, congenital heart disease, ischemic heart disease, cardiomyopathy, aortic valve disease, and noncompaction (8). The interpretation of inverted T-waves is problematic in children and teenagers. It is normal for T-waves in the precordial leads to invert from a few days of life to adolescence. Therefore, inverted T-waves in athletes younger than 16 yr are not necessarily indicative of pathology (36).

In addition to the ECG, a 24-h Holter, 30-d event monitor, and/or exercise test are used by pediatric cardiologists to try to document the heart rhythm during episodes of palpitations. These tests also provide reassurance when palpitations are sensed but no malignant arrhythmia is

TABLE 4.

Additional studies used in the initial cardiac evaluation of athletes.

Study	Positive Findings	Example of Possible Cardiac Diagnosis
Echocardiogram	Asymmetric septal hypertrophy; left ventricle outflow obstruction	HCM
	Right ventricle dilation; right ventricle dysfunction	ARVD
	Anomalous origin or course of coronary artery	Coronary artery anomaly
	Aneurysmal coronary artery	History of Kawasaki disease
	Aortic root dilatation	Bicuspid aortic valve; connective tissue disease (e.g., Marfan)
	Aortic stenosis	Bicuspid aortic valve; congenital aortic stenosis
	Coarctation of the aorta	Coarctation of the aorta
	Dilated ventricle with decreased function	Dilated cardiomyopathy; history of myocarditis
24-h Holter monitor 30-d event monitor	Supraventricular tachycardia	Wolff-Parkinson-White syndrome; multifocal atrial tachycardia; ectopic atrial tachycardia; atrioventricular reentrant tachycardia; AV nodal reentry tachycardia; atrial flutter/fibrillation
	Ventricular tachycardia and/or ventricular fibrillation	Arrhythmia syndromes (e.g., long QT, Brugada, catecholaminergic polymorphic ventricular tachycardia); ARVD, HCM
Exercise testing	QT lengthens	Long QT syndrome
	QT shortens	Benign
	Premature ventricular contractions suppressed	Benign
	Ventricular tachycardia	Arrhythmia syndromes; ARVD, HCM

ARVD = arrhythmogenic right ventricular dysplasia; HCM = hypertrophic cardiomyopathy.

found. In lieu of electrophysiological documentation of irregular rhythms, the following historical information would increase concern for arrhythmias in athletes: significant tachycardia >220 bpm, associated symptoms of lightheadedness and/or syncope, and family history of early sudden death (6). Abnormal ECG findings often lead to an echocardiogram among other tests to search for a cardiac diagnosis. Table 4 presents an example of cardiac conditions suggested by positive findings from additional tests.

A pediatric cardiologist may have a low threshold to perform an echocardiogram, partly due to ease in obtaining the study in the office, and partly due to concerns relayed from the family and primary care provider regarding the need to provide “sports clearance” for the athlete. There often is a time pressure involved once the patient is referred to the pediatric cardiologist’s office due to the imminent start of a sports season or summer camp. Even after a thorough cardiac evaluation, the pediatric cardiologist cannot be 100% certain that the patient will not experience sudden death during sports. The medical-legal aspects of providing sports clearance is a significant concern for subspecialists although beyond the scope of this paper.

SPORTS MEDICINE PERSPECTIVE

There is a continuing debate as to whether to screen all athletes with ECG (Table 5). Sudden death is a very uncommon event that happens to an estimated 75 athletes per year in the United States, but only about 30% are not likely to be caught by an ECG (31). In a recent study by

Stanford University, a group of college athletes underwent a preparticipation exam including a history, physical exam, and an ECG screening. Of the athletes, 10% were found to have abnormal ECG findings and obtained further testing (22). The cost effectiveness study showed that ECG screening saved 2.06 life years per 1000 athletes, at a cost of \$89 per athlete and a ratio of \$42,900 per life saved (51). In comparison, older data from 2000 suggested the cost of the history and physical alone, which costs \$84,000 per year of life saved (14). Some argue that only professional and collegiate athletes should be screened with an ECG since they are more competitive. Most of the data supporting screening athletes with ECG is from research from Italy (7,40,42). Because Italy only has an athlete population of 6 million compared with 15 million in the United States, it is feasible for them to only screen highly competitive athletes (7). However, this can be perceived as discriminating and unfair. Sudden deaths mostly occur in nonathletes; therefore, limiting ECG to competitive athletes may result in missed cases in the general pediatric population, which would entail screening all 75 million children in the United States (25). The AHA estimates that it would cost approximately \$2 billion annually to implement an ECG program to screen all of these children (28). Although the AHA doesn’t recommend mandatory ECG screenings in athletes, it does encourage the volunteer efforts in different high schools, colleges, and communities. Certainly, improvement in preparticipation screening of conditions associated with sudden cardiac death is needed and deserves further research.

TABLE 5.**Pros and cons of ECG screening in young athletes.**

Pros	Cons
Cardiovascular screening for young competitive athletes is justifiable on ethical, legal, and medical grounds (38).	ECG screening of athletes have a high false positive rate (16.9%–40% rate of false positives (2,21).
Sudden death is estimated to occur in two in 100,000 high-school athletes each year (30).	False positive ECG tests can cause anxiety and unnecessary removal of athletes from sports.
Incidence of sudden deaths before and after implementation of screening fell by 89% in Italy (7).	Physicians need to be willing to work extra in order to do the screenings.
ECG improved the sensitivity (90.9%) compared with no ECG (45.5%) (2) and the negative predictive value from 98.7% to 99.8% (38).	Physicians may not feel trained enough to conduct cardiac screenings for athletes (25).
Large organizations support screening of competitive athletes including the European Society of Cardiology and International Olympic Committee (37).	Screening for sudden cardiac death program may not be a top health care priority (39).
Costs are equivalent with other life-saving treatments considering cost per year of life saved.	An ECG screening program could cost approximately \$2 billion annually for testing in the United States (51).
Specific populations are at higher risk for hypertrophic cardiomyopathy (e.g., African-American athletes).	Italian studies involved a homogeneous ethnic group and may not represent other populations.
There is a need to continue to improve the preparticipation physical exam and cardiac screening process.	ECG criteria for abnormalities in young athletes is not established fully.

ECG = electrocardiogram.

Sports medicine and primary care physicians who perform regular preparticipation examinations raise many practical concerns. These concerns include medicolegal, technical, and logistical issues. Fortunately, there is little precedent for successful medicolegal suits against physicians for sports-medicine related issues, especially with regard to the preparticipation physical exam (32). As in all areas of medicine, the principle of practicing the standard of care equal to what would be practiced reasonably by a colleague with a similar level of experience would hold. Following procedures and using paperwork outlined in the recent *PPE Preparticipation Physical Evaluation* (4th Edition) monograph (1), which recently was published and endorsed by several leading primary care and sports medicine organizations, is recommended, as this provides a reasonable standard of what is expected. Where and how an exam is conducted have implications for the ownership and accessibility of the exam record. Physicians' records are protected by the Health Insurance Portability and Accountability Act (HIPAA), and records of exams performed at school are covered under the Family Education Rights and Privacy Act of 1974 (1).

Sports medicine or primary care physicians may perform large numbers of preparticipation physical exams in a large clinic or at schools, which can be a daunting and time-consuming task. Often, more than one physician and other staff members are involved, and the mass screenings are conducted in stations. Pieces of the cardiac examination are divided typically into the following: 1) review of the history questionnaire, 2) recording of vital signs (pulse, blood pressure), and 3) the medical portions of the physical examination. It is recommended that the health professional who is completing the preparticipation exam form review the details of the cardiac examination before authorizing

participation of the athlete. Having adequate staff members who are trained to perform their tasks can facilitate and optimize the preparticipation exam process. Staff members can review the questions before the physician repeats the review to make sure there are not any red flags. The history and consent form must be completed appropriately, including a parent's signature. It is extremely useful to have the parent review the form, as research demonstrates that the history is more accurate when the parent helps complete the form (5). Finally, at minimum, parental contact information, or even better, the primary care physician and medical insurance information, can be useful to facilitate any necessary follow-up. An automated blood pressure cuff can be useful, especially if there are numerous athletes and the assessment area is noisy. The appropriate sized cuff should be used, and any spurious values should be repeated in a quiet room with a standard blood pressure cuff and stethoscope. Similarly, the medical examination portion should be conducted in a private, quiet area so that the physician can auscultate the heart properly. A portable athlete examination table set at an appropriate height is useful to facilitate the supine and standing auscultation maneuvers. Knowledge of the student population you are serving as well as the referral sources for cardiology care in your community is useful. Building a referral network of specialists who are interested in dealing with cardiac issues in young athletes is extremely helpful.

CONCLUSION

The primary care practitioner is encouraged to perform a focused cardiovascular history and physical exam in the office or other setting as part of the standard of care for a sports preparticipation visit. This is an important first

step in the evaluation of a patient who may then go on to further testing and specialist referral as needed. Although community-based screenings with ECGs of young athletes in the United States may become routine at some point in the future, currently they are not performed widely because of concerns regarding false positives, false negatives, and screening costs. In the meantime, refinement of the cardiovascular focused history and physical in athletes may help identify risk factors for sudden cardiac death and lead to appropriate referral for detailed cardiac evaluation.

References

1. American Academy of Pediatrics. *PPE Preparticipation Physical Evaluation, Fourth Edition*. American Academy of Pediatrics; 2010.
2. Baggish AL, Hutter AM Jr, Wang F, et al. Cardiovascular screening in college athletes with and without electrocardiography: a cross-sectional study. *Ann. Intern. Med.* 2010; 152:269–75.
3. Basavarajiah S, Boraita A, Whyte G, et al. Ethnic differences in left ventricular remodeling in highly-trained athletes relevance to differentiating physiologic left ventricular hypertrophy from hypertrophic cardiomyopathy. *J. Am. Coll. Cardiol.* 2008; 51:2256–62.
4. Basso C, Maron BJ, Corrado D, Thiene G. Clinical profile of congenital coronary artery anomalies with origin from the wrong aortic sinus leading to sudden death in young competitive athletes. *J. Am. Coll. Cardiol.* 2000; 35:1493–501.
5. Carek PJ, Futrell M, Hueston WJ. The preparticipation physical examination history: who has the correct answers? *Clin. J. Sport Med.* 1999; 9:124–8.
6. Colman N, Bakker A, Linzer M, et al. Value of history-taking in syncope patients: in whom to suspect long QT syndrome? *Europace*. 2009; 11:937–43.
7. Corrado D, Basso C, Pavei A, et al. Trends in sudden cardiovascular death in young competitive athletes after implementation of a preparticipation screening program. *JAMA*. 2006; 296:1593–601.
8. Corrado D, Pelliccia A, Heidbuchel H, et al. Recommendations for interpretation of 12-lead electrocardiogram in the athlete. *Eur. Heart J.* 2010; 31:243–59.
9. D'Andrea A, Riegler L, Cocchia R, et al. Left atrial volume index in highly trained athletes. *Am. Heart J.* 2010; 159:1155–61.
10. Danduran MJ, Earing MG, Sheridan DC, et al. Chest pain: characteristics of children/adolescents. *Pediatr. Cardiol.* 2008; 29:775–81.
11. Drezner JA, Chun JS, Harmon KG, Derminer L. Survival trends in the United States following exercise-related sudden cardiac arrest in the youth: 2000–2006. *Heart Rhythm*. 2008; 5:794–9.
12. Evangelista JA, Parsons M, Renneburg AK. Chest pain in children: diagnosis through history and physical examination. *J. Pediatr. Health Care*. 2000; 14:3–8.
13. Fitzsimmons PJ, McWhirter PD, Peterson DW, Kruyer WB. The natural history of Wolff Parkinson-White syndrome in 228 military aviators: a long-term follow-up of 22 years. *Am. Heart J.* 2001; 142:530–6.
14. Fuller CM. Cost effectiveness analysis of screening of high school athletes for risk of sudden cardiac death. *Med. Sci. Sports Exerc.* 2000; 32:887–90.
15. Graham TP Jr, Driscoll DJ, Gersony WM, et al. Task Force 2: congenital heart disease. *J. Am. Coll. Cardiol.* 2005; 45:1326–33.
16. Hancock EW, Deal BJ, Mirvis DM, et al. AHA/ACCF/HRS recommendations for the standardization and interpretation of the electrocardiogram: part V: electrocardiogram changes associated with cardiac chamber hypertrophy: a scientific statement from the American Heart Association Electrocardiography and Arrhythmias Committee, Council on Clinical Cardiology; the American College of Cardiology Foundation; and the Heart Rhythm Society. Endorsed by the International Society for Computerized Electrocardiology. *J. Am. Coll. Cardiol.* 2009; 53:992–1002.
17. Heidbuchel H, Panhuyzen-Goedkoop N, Corrado D, et al. Recommendations for participation in leisure-time physical activity and competitive sports in patients with arrhythmias and potentially arrhythmogenic conditions, part I: supraventricular arrhythmias and pacemakers. *Eur. J. Cardiovasc. Prev. Rehabil.* 2006; 13:475–84.
18. Kane DA, Fulton DR, Saleeb S, et al. Needles in hay: chest pain as the presenting symptom in children with serious underlying cardiac pathology. *Congenit. Heart Dis.* 2010; 5:366–73.
19. Klein GJ, Bashore TM, Sellers TD, et al. Ventricular fibrillation in the Wolff-Parkinson-White syndrome. *N. Engl. J. Med.* 1979; 301:1080–5.
20. La Gerche A, Taylor AJ, Prior DL. Athlete's heart: the potential for multimodality imaging to address the critical remaining questions. *JACC Cardiovasc. Imaging*. 2009; 2:350–63.
21. Lawless CE, Best TM. Electrocardiograms in athletes: interpretation and diagnostic accuracy. *Med. Sci. Sports Exerc.* 2008; 40:787–98.
22. Le VV, Wheeler MT, Mandic S, et al. Addition of the electrocardiogram to the preparticipation examination of college athletes. *Clin. J. Sport Med.* 2010; 20:98–105.
23. Maraj S, Figueredo VM, Lynn Morris D. Cocaine and the heart. *Clin. Cardiol.* 2010; 33:264–9.
24. Marcus F, Towbin JA, Zareba W, et al. Arrhythmogenic right ventricular dysplasia/cardiomyopathy (ARVD/C): a multidisciplinary study: design and protocol. *Circulation*. 2003; 107:2975–8.
25. Maron BJ. National electrocardiography screening for competitive athletes: feasible in the United States? *Ann. Intern. Med.* 2010; 152:324–6.
26. Maron BJ. Structural features of the athlete heart as defined by echocardiography. *J. Am. Coll. Cardiol.* 1986; 7:190–203.
27. Maron BJ. Hypertrophic cardiomyopathy and other causes of sudden cardiac death in young competitive athletes, with considerations for preparticipation screening and criteria for disqualification. *Cardiol. Clin.* 2007; 25:399–414.
28. Maron BJ, Araujo CG, Thompson PD, et al. Recommendations for preparticipation screening and the assessment of cardiovascular disease in masters athletes: an advisory for healthcare professionals from the working groups of the World Heart Federation, the International Federation of Sports Medicine, and the American Heart Association Committee on Exercise, Cardiac Rehabilitation, and Prevention. *Circulation*. 2001; 103:327–34.
29. Maron BJ, Carney KP, Lever HM, et al. Relationship of race to sudden cardiac death in competitive athletes with hypertrophic cardiomyopathy. *J. Am. Coll. Cardiol.* 2003; 41:974–80.
30. Maron BJ, Doerer JJ, Haas TS, et al. Sudden deaths in young competitive athletes: analysis of 1866 deaths in the United States, 1980–2006. *Circulation*. 2009; 119:1085–92.
31. Maron BJ, Haas TS, Doerer JJ, et al. Comparison of U.S. and Italian experiences with sudden cardiac deaths in young competitive athletes and implications for preparticipation screening strategies. *Am. J. Cardiol.* 2009; 104:276–80.
32. Maron BJ, Mitten MJ, Quandt EF, Zipes DP. Competitive athletes with cardiovascular disease — the case of Nicholas Knapp. *N. Engl. J. Med.* 1998; 339:1632–5.
33. Maron BJ, Thompson PD, Ackerman MJ, et al. Recommendations and considerations related to preparticipation screening for cardiovascular abnormalities in competitive athletes: 2007 update: a scientific statement from the American Heart Association Council on Nutrition, Physical Activity, and Metabolism: endorsed by the American College of Cardiology Foundation. *Circulation*. 2007; 115:1643–55.
34. Massin MM, Benatar A, Rondia G. Epidemiology and outcome of tachyarrhythmias in tertiary pediatric cardiac centers. *Cardiology*. 2008; 111:191–6.
35. O'Connor FG, Meyering CD, Patel R, Oriscello RP. Hypertension, athletes, and the sports physician: implications of JNC VII, the Fourth Report, and the 36th Bethesda Conference Guidelines. *Curr. Sports Med. Rep.* 2007; 6:80–4.
36. Papadakis M, Basavarajiah S, Rawlins J, et al. Prevalence and significance of T-wave inversions in predominantly Caucasian adolescent athletes. *Eur. Heart J.* 2009; 30:1728–35.
37. Pelliccia A. The preparticipation cardiovascular screening of competitive athletes: is it time to change the customary clinical practice? *Eur. Heart J.* 2007; 28:2703–5.
38. Pelliccia A, Corrado D. Can electrocardiographic screening prevent sudden death in athletes? Yes. *BMJ*. 2010; 341:c4923.
39. Pelliccia A, Corrado D. Electrocardiography and preparticipation screening of competitive high school athletes. *Ann. Intern. Med.* 2010; 153:132.
40. Pelliccia A, Di Paolo FM, Corrado D, et al. Evidence for efficacy of the Italian national pre-participation screening programme for identification of hypertrophic cardiomyopathy in competitive athletes. *Eur. Heart J.* 2006; 27:2196–200.

41. Pelliccia A, Di Paolo FM, Maron BJ. The athlete's heart: remodeling, electrocardiogram and preparticipation screening. *Cardiol. Rev.* 2002; 10:85–90.
42. Pelliccia A, Di Paolo FM, Quattrini FM, *et al.* Outcomes in athletes with marked ECG repolarization abnormalities. *N. Engl. J. Med.* 2008; 358: 152–61.
43. Phillips B. The JNC 7 hypertension guidelines. *JAMA.* 2003; 290: 1314.
44. Pluim BM, Zwinderman AH, van der Laarse A, van der Wall EE. The athlete's heart. A meta-analysis of cardiac structure and function. *Circulation.* 2000; 101:336–44.
45. Sharma S, Maron BJ, Whyte G, *et al.* Physiologic limits of left ventricular hypertrophy in elite junior athletes: relevance to differential diagnosis of athlete's heart and hypertrophic cardiomyopathy. *J. Am. Coll. Cardiol.* 2002; 40:1431–6.
46. Singh A, Silberbach M. Consultation with the specialist: cardiovascular preparticipation sports screening. *Pediatr. Rev.* 2006; 27:418–24.
47. Stout M. The Marfan syndrome: implications for athletes and their echocardiographic assessment. *Echocardiography.* 2009; 26:1075–81.
48. Vanberg P, Atar D. Androgenic anabolic steroid abuse and the cardiovascular system. *Handb. Exp. Pharmacol.* 2010; 195:411–57.
49. Vianna CB, Gonzalez MM, Dallan LA, *et al.* Anomalous coronary artery causing transmural ischaemia and ventricular tachycardia in a high school athlete. *Resuscitation.* 2007; 74:183–6.
50. Walsh CA. Syncope and sudden death in the adolescent. *Adolesc. Med.* 2001; 12:105–32.
51. Wheeler MT, Heidenreich PA, Froelicher VF, *et al.* Cost-effectiveness of preparticipation screening for prevention of sudden cardiac death in young athletes. *Ann. Intern. Med.* 2010; 152:276–86.